

## Correlation of Hemostatic Molecular Markers and Morphology of the Residual False Lumen in Chronic Aortic Dissection

Katsuyoshi Iyano, MD, Tadanori Kawada, MD, PhD, Masahiro Aiba, MD, PhD,  
and Toshihiro Takaba, MD, PhD

We evaluated our hypothesis that morphological change of the aortic dissection can be predicted by serial measurements of hemostatic molecular markers. Between February 1999 and February 2003, 50 patients with chronic aortic dissection of the descending thoracic aorta were studied at random intervals of 1 to 59 months (mean, 15.4±14.3) after onset. Morphologies of the false lumen of the aortic dissection determined by computed tomographic (CT) images were divided into four groups. Twenty-two images had aortic dissection associated with intramural hematoma or a completely thrombosed false lumen without ulcer-like projections (group 1), 14 had a thrombosed false lumen with ulcer-like projections (group 2), 18 had patent, but a partially thrombosed false lumen (group 3), and 15 had a completely patent false lumen (group 4). Blood samples for detection of hemostatic molecular markers were collected on the same day or within 1 month of the CT scan being performed. Thrombin-antithrombin complex (TAT) and D-dimer proved to be significantly higher in group 3 than in group 1. There was no significant correlation between the external diameter and hemostatic molecular markers except for prothrombin fragments 1+2 (PTF1+2). Simultaneous determinations of these hemostatic markers and multiple CT scans were performed more than twice in 19 of the patients. These cases were divided into three groups according to the morphological changes of the false lumen in the interval; morphologically progressive, regressive and no change cases. Five cases showed reduction or disappearance of the false lumen (the regressive cases). Only one case showed that the false lumen progressively enlarged and was partially patent thereafter (the progressive case). Mean plasma levels of TAT and D-dimer were changed correlated with the morphological progressive or regressive changes. The morphology of aortic dissection was correlated with hemostatic molecular markers such as TAT or D-dimer. We concluded that the serial measurement of D-dimer and TAT is useful for predicting morphological changes in chronic aortic dissection, and it can be an alternative way to follow up for patients of aortic dissection. (*Ann Thorac Cardiovasc Surg* 2004; 10: 106–12)

**Key words:** hemostatic molecular marker, chronic aortic dissection, coagulopathy, thrombin-antithrombin complex (TAT), D-dimer

### Introduction

Patients with aortic dissection who survive an acute stage require regular CT scans or angiography over a long-term follow-up.<sup>1)</sup> However, there are problems such as expo-

*From First Department of Surgery, Showa University School of Medicine, Tokyo, Japan*

Received June 17, 2003; accepted for publication October 1, 2003. Address reprint requests to Katsuyoshi Iyano, MD: First Department of Surgery, Showa University School of Medicine, 1-5-8 Hatanodai, Shinagawa-ku, Tokyo 142-8555, Japan.

sure to radiation, or allergic reactions and renal impairment due to the use of contrast dye. If an alternative noninvasive diagnostic method to predict morphological variations in aortic dissection were available, it would help to eliminate these risks. Increased plasma levels of hemostatic molecular markers induced by in-vivo activation of platelets and the coagulofibrinolytic cascade are reported to correlate strongly with maximal aortic size and progression of coagulopathy in chronic aortic dissection.<sup>2)</sup> We postulated that these markers would also be influenced by morphological variations in false lumen of

the aortic dissection. Thus, relationships between plasma levels of these molecular markers and the morphology of the residual false lumen or aortic size determined by simultaneously performed computed tomographic (CT) images were analyzed to evaluate whether our hypothesis, that morphological change of the aortic dissection can be predicted by serial measurements of these markers, was supportable.

## Materials and Methods

Between February 1999 and February 2003, 50 patients (34 males and 16 females, aged from 26 to 86 years; mean  $61.1 \pm 13.0$ ) with chronic aortic dissection were treated at the Showa University Hospital. Chronic aortic dissection was defined as more than 1 month passing since the chest or back pain developed. Subsequently, aortic dissection in all patients was mainly diagnosed by contrast enhanced CT scan, which was performed at random intervals during the period 1 to 59 months (mean,  $15.4 \pm 14.3$ ) after onset. Fourteen patients had the DeBakey's type I aortic dissection and 36 type III. Serum levels of hemostatic molecular markers were measured on the same day or within one month of the CT scan being performed. The maximal diameter of the thoracic aorta involved in the dissection process was measured in all patients. Twelve patients had undergone a previous aortic operation; ascending aortic replacement in eight, total arch replacement in one, descending thoracic aortic replacement in one and endovascular stent graft repair at the descending thoracic aorta in two (Table 1).

### Morphology of the residual aortic dissection

Sixty-nine CT images from 50 patients were divided into four groups according to morphological variations in aortic dissection; 22 had aortic dissection associated with intramural hematoma (IMH) or a completely thrombosed false lumen without ulcer-like projections (ULP) (group 1), 14 had a thrombosed false lumen associated with ulcer-like projections anywhere at the dissected segments (group 2), 18 had a patent false lumen that was partially thrombosed (group 3), and 15 had a completely patent false lumen without thrombosis (group 4).

### Hemostatic markers

Hemostatic markers determined were platelet count (Plt) (normal range,  $13-35 \times 10^4/\text{mm}^3$ ),  $\beta$ -thromboglobulin ( $\beta$ -TG) (normal level  $<50 \text{ ng/ml}$ ) and platelet factor 4 (PF-4) ( $<20 \text{ ng/ml}$ ) as thrombocytic markers; fibrinogen ( $200-400 \text{ mg/}$

**Table 1. Patients characteristics**

|                                      |                 |
|--------------------------------------|-----------------|
| Patients                             | 50              |
| CT images                            | 69              |
| Male/female                          | 34/16           |
| Age (yr: mean $\pm$ SD)              | $61.1 \pm 13.0$ |
| Follow-up (month: mean $\pm$ SD)     | $15.4 \pm 14.3$ |
| Maximal diameter (mm: mean $\pm$ SD) | $36.6 \pm 7.6$  |
| DeBakey's classification             |                 |
| Type I                               | 14              |
| III                                  | 36              |
| Previous operation                   |                 |
| Ascending aorta replacement          | 8               |
| Total arch replacement               | 1               |
| Descending aortic replacement        | 1               |
| Endovascular stent graft             | 2               |

dl), thrombin-antithrombin complex (TAT) ( $<3 \text{ ng/ml}$ ) and prothrombin fragments 1+2 (PTF1+2) ( $0.4-1.4 \text{ nmol/L}$ ) as coagulation markers; and D-dimer ( $<1.0 \mu\text{g/ml}$ ) as a fibrinolytic marker.  $\beta$ -TG, PF-4 and TAT concentrations were measured by enzyme immunoassays, PTF1+2 concentrations by enzyme-linked immunosorbent assay and D-dimer by latex photometric immunoassay.

### Changes in hemostatic markers correlating to the morphological change in the aortic dissection

Simultaneous determinations of these hemostatic markers and multiple CT scans were performed more than twice in 19 of the patients. These cases were divided into three groups according to the morphological changes of the false lumen in the interval; morphologically progressive, regressive and no change cases.

### Statistical analysis

All continuous data were expressed as means  $\pm$  standard deviations. Comparisons among groups were made using the two-way Kruskal-Wallis H-test. When the analysis indicated a significant effect, the Mann-Whitney U-test with Bonferroni correction as a post hoc test was performed for multiple comparisons. Wilcoxon t-test was used for evaluation of morphological changes of the aortic dissection and hemostatic parameters. P values less than 0.05 were considered to indicate a statistically significant differences.

## Results

There were no significant differences in follow-up periods among the four groups. The maximal diameter of the descending thoracic aorta involved in aortic dissection

**Table 2. Comparative characteristics of the groups**

|                       | Group 1 (n=21) | Group 2 (n=14) | Group 3 (n=18) | Group 4 (n=15) |
|-----------------------|----------------|----------------|----------------|----------------|
| Follow-up (month)     | 7.0±7.1        | 11.0±12.3      | 20.8±16.0      | 8.6±11.6       |
| Maximal diameter (mm) | 30.6±8.8       | 37.8±6.2*      | 40.5±6.9*      | 36.3±10.9      |

\*p<0.05

There were significant differences in maximal diameter in group 3 than that in group 1.

was significantly larger in group 3 than that in group 1 (Table 2).

**Thrombocytic markers**

Platelet counts were maintained within normal limits in almost all patients. Apparent thrombocytopenia likely to induce spontaneous bleeding was not observed, even in patients in whom extensive thrombus formation in the false lumen was demonstrated. There were no significant differences in platelet counts among the groups. Mean plasma levels of  $\beta$ -TG and PF-4 were somewhat higher than normal limits in all groups. However, there were no significant differences detected among the groups (Fig. 1).

**Coagulation markers**

Mean plasma levels of TAT were higher than normal limits in groups 2, 3 and 4; and were significantly higher in group 3 than in 1, however there were no significant differences

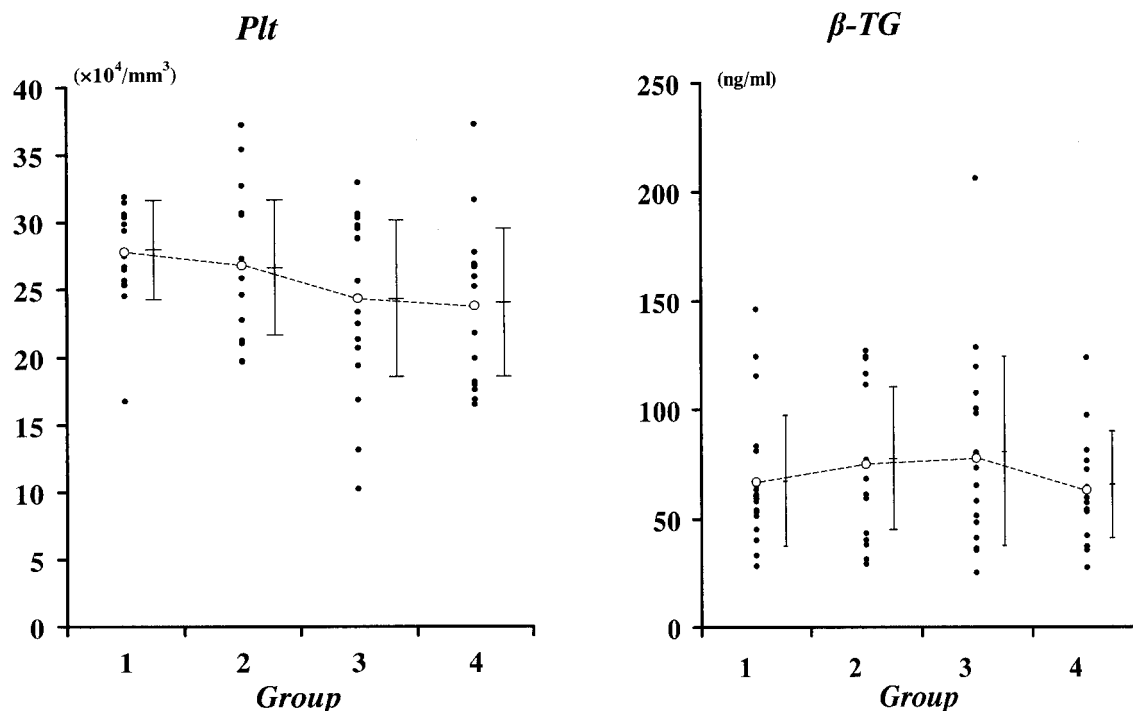
between groups 1 and 2 or 4 (Fig. 2). Mean plasma levels of PTF1+2 were somewhat higher in groups 2, 3 and 4 as compared to 1; however, no statistically significant differences were detected. There were also no significant differences in plasma fibrinogen levels among the groups.

**Fibrinolytic markers**

Mean plasma levels of D-dimer were higher than normal in groups 2, 3 and 4; significantly higher in group 3 than in 1, but there were no significant differences between groups 1 and 2 or 4 (Fig. 2).

**Correlations between the maximal diameter of the aorta and each marker**

There were significant correlations between the maximal diameter of the aorta and PTF1+2 (Fig. 3). However, maximal diameter was not correlated to platelet count, fibrinogen,  $\beta$ -TG, PF-4, TAT or D-dimer.



**Fig. 1.** No significant differences in platelet counts and  $\beta$ -TG among the groups.

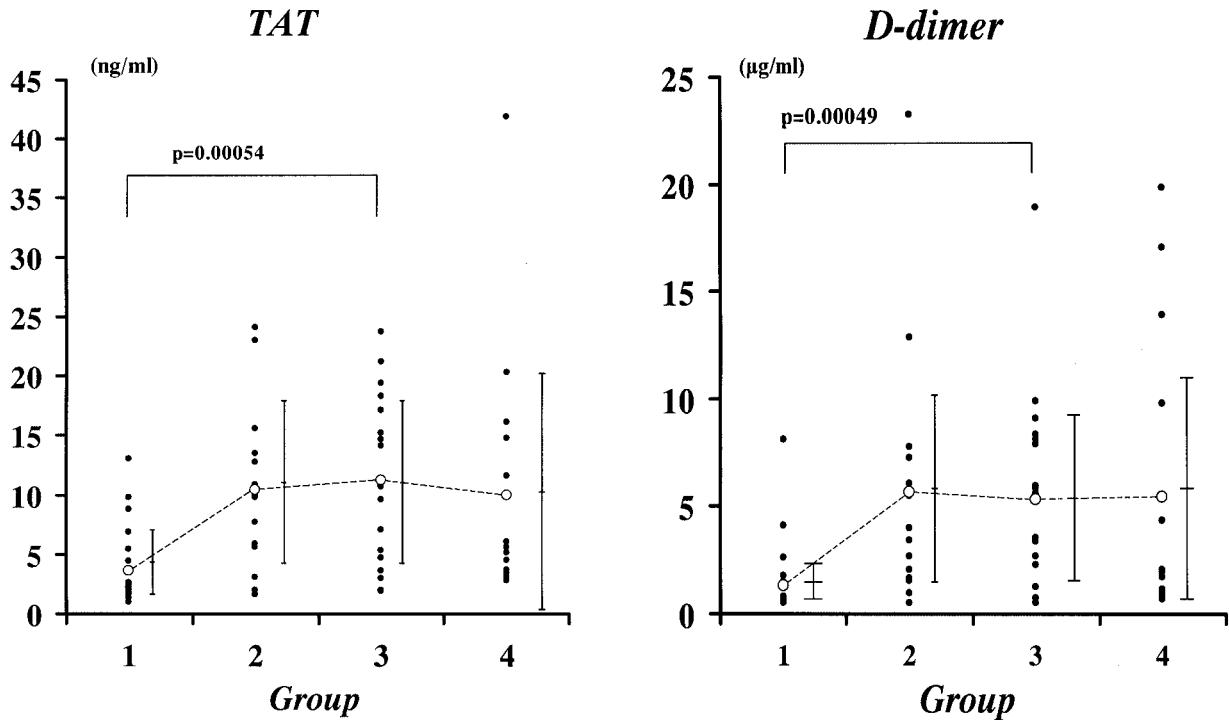


Fig. 2. TAT and D-dimer were significantly higher in group 3 than in 1.

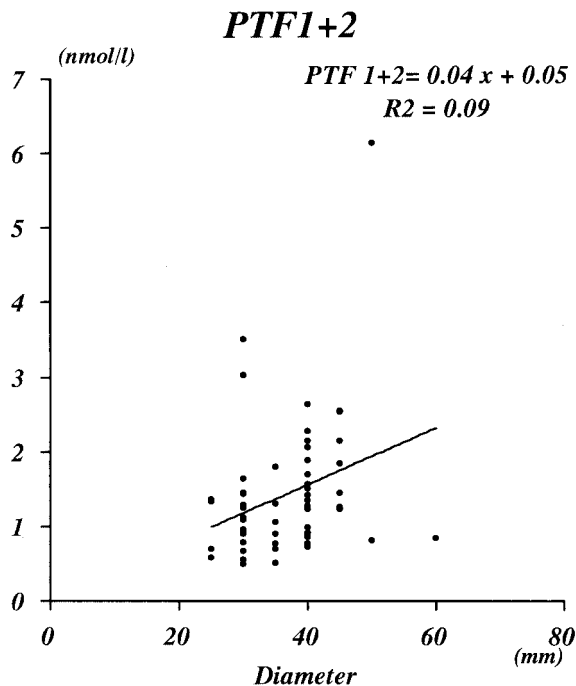


Fig. 3. Significant correlations between maximal diameter of the aorta and PTF1+2 concentrations.

**Changes in hemostatic markers correlating to morphological changes in the aortic dissection**

Five cases that showed reduction or disappearance of the

false lumen were classified as regressive. Mean plasma levels of TAT and D-dimer were decreased in correlation with the morphological regressive changes. The one case that showed the false lumen progressively enlarging and being partially patent thereafter was classified as progressive. Plasma levels of TAT and D-dimer increased with the progressive change of the morphology. The other 13 cases were classified as no change, and showed no tendency to increase or decrease (Fig. 4).

Two typical cases of the progressive and regressive types, in which the markers changed in correlation with morphological changes of the aortic dissection on CT images, are presented. A 50-year-old female was classified as group 1; plasma levels of TAT were slightly elevated but D-dimer was within a normal range during the early stage of the aortic dissection. Half a month later, when the D-dimer level was elevated in spite of steady TAT levels, the false lumen concurrently became thicker and partially patent at the middle of the descending thoracic aorta. The morphology of the false lumen converted to group 3; though the same aortic morphology and higher levels of D-dimer continued thereafter. CT images in Fig. 5 are sliced at the same level of the middle descending thoracic aorta (Fig. 5).

The other case is a 76-year-old male who was classified as group 4 at onset; TAT and D-dimer levels showed

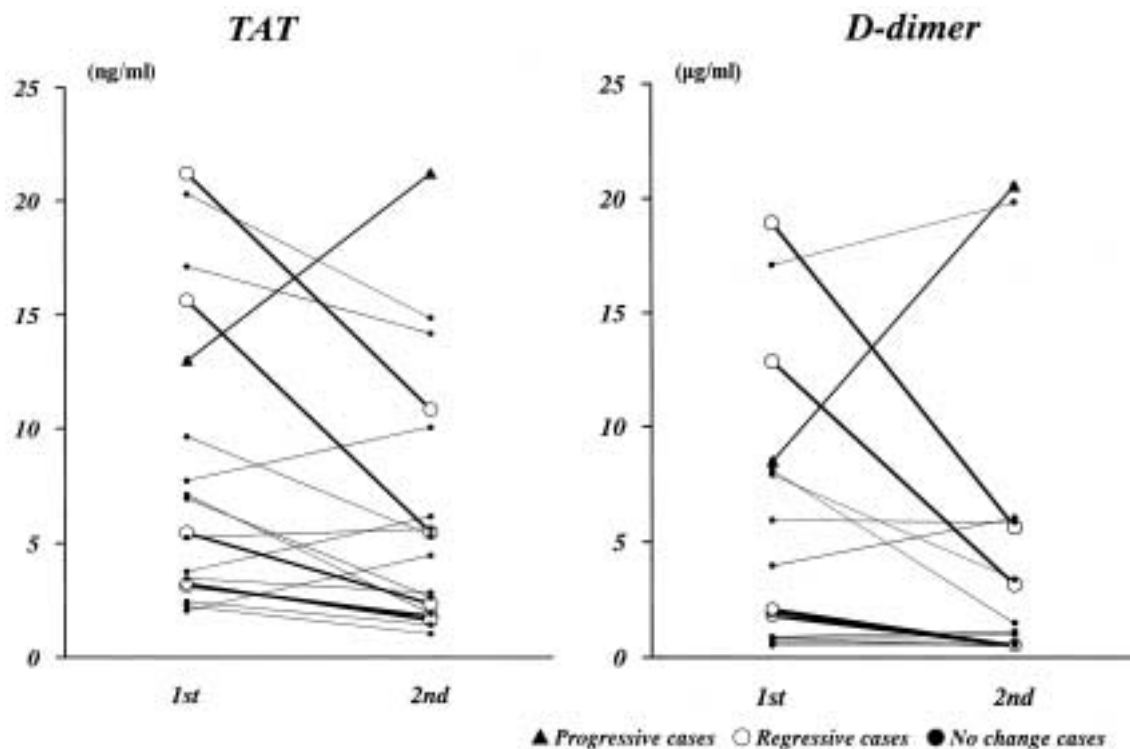


Fig. 4. Study of morphological changes in the interval. TAT and D-dimer changed in correlation to the morphological changes of the aortic dissection.

higher than normal ranges. One and a half months later, the false lumen was completely thrombosed and had disappeared; the TAT and D-dimer levels concomitantly decreased. Four months later, the D-dimer level had decreased to a normal range.

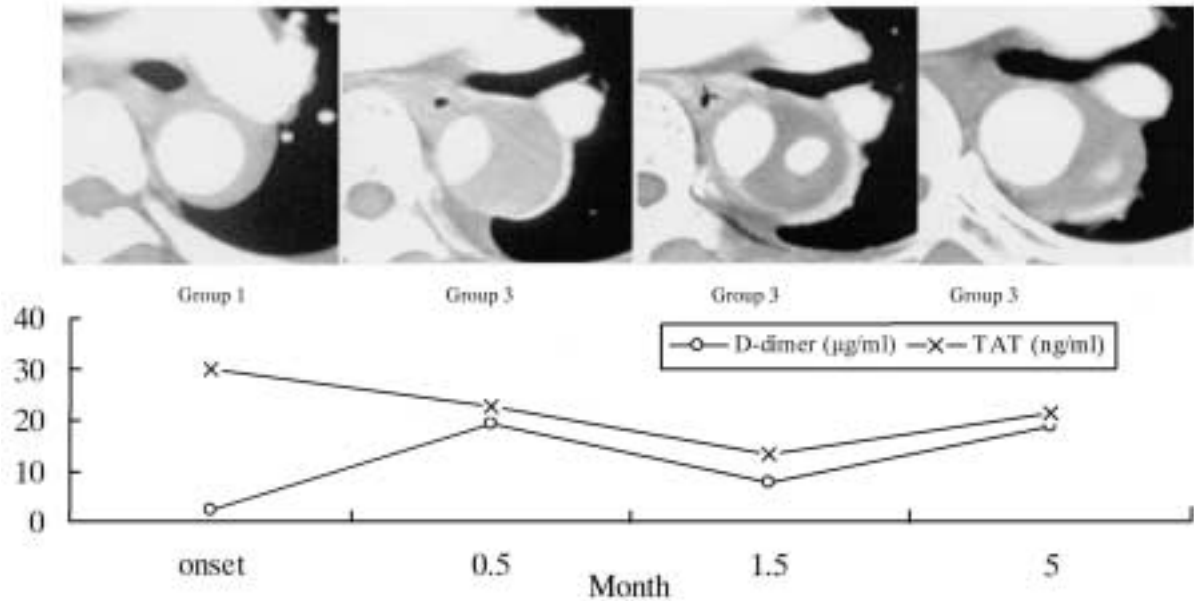
## Discussion

Since Fine et al.<sup>3)</sup> first described the condition in 1967, there have been many reports of the association of coagulopathy in acute or chronic aortic dissections; clinical manifestation of coagulopathy such as petechiae, gingival bleeding and prolonged bleeding from venipuncture sites are not uncommon in acute aortic dissection.<sup>3-5)</sup> Indeed, uncontrollable bleeding sometimes develops during operations for aortic dissection. Neri et al. recommended preoperative supplement of platelet or coagulation factors to correct coagulation abnormalities in emergency surgery for acute aortic dissection, especially in elderly patients.<sup>6)</sup>

Patients with aortic dissection who survive an acute stage require regular CT scans or angiography over periods of long-term follow-up.<sup>1)</sup> However, there are problems such as exposure to radiation, or allergic reactions

and renal impairment due to the use of contrast dye. If an alternative noninvasive diagnostic method to predict morphological variations in aortic dissection were available, it would help to eliminate these risks. We thus undertook this study to evaluate whether periodical measurements of hemostatic molecular markers, reflected in in-vivo activation of platelets and the coagulofibrinolytic cascade, were reliable predictors of morphological changes of the false lumen or aortic size in chronic aortic dissection, and whether they would also be informative for long-term follow-ups.

Platelets play an initiative role in thrombus formation in high-shear stress areas of the aorta and arterial trees. Exposure of subendothelial aortic tissues, like collagen fibers and smooth muscle, has been shown to lead to massive deposition of platelets.<sup>7,8)</sup> In this study, platelet counts were well maintained in most patients, and there were no statistically significant differences in mean platelet counts among the four groups. Apparent thrombocytopenia, to an extent that might result in a bleeding tendency, was not observed even in patients with a large false lumen surface area associated with extensive thrombus formation.  $\beta$ -TG and PF-4 are very sensitive molecular markers that reflect in-vivo platelet activations.<sup>9)</sup> Prior to this



**Fig. 5.** Progressive case. A 50-year-old female classified to group 1; plasma levels of D-dimer within normal range during the early stage, but when the D-dimer level was elevated, the morphology of the false lumen was converted to group 3; the false lumen concurrently became thicker and partially patent at the middle of the descending thoracic aorta. (CT images are sliced at the same level of the middle descending thoracic aorta.)

study we postulated that these markers might be greatly effected in patients who had a patent or partially thrombosed false lumen. However, significant differences in mean values of these markers were not demonstrated among the groups, although relatively higher levels in  $\beta$ -TG were demonstrated in groups 2 and 3, as compared to 1. These results suggested that patients with platelet consumption accentuated to the degree of inducing a negative production/consumption balance of platelets might be rare in chronic aortic dissection. The short half life of these platelet specific proteins in blood, and the possibility that these markers are too sensitive to differentiate morphological variations of the aortic dissection, seems to be why plasma levels of these markers did not show any differences among the groups.

Although the aortic endothelial layer possesses very weak thromboplastic properties, the atherosclerotic aorta has strong thromboplastic and fibrinolytic activity, as does the aortic adventitia.<sup>11)</sup> Coagulation abnormalities in aortic dissection have been reported to be induced by three possible mechanisms: first, by activation of factor XII by contacting the subendothelial tissues, especially collagen, leading to the activation of the intrinsic coagulation pathway; second, the activation of factor VII by tissue factors of the aortic wall; third, activated fibrinolysis is triggered by tissue plasminogen activator (tPA), an activity of which

mainly presents in the aortic adventitia.<sup>11)</sup> The first two mechanisms activate factor V, the gateway protein of the common coagulation cascade, leading to a rapid and explosive generation of thrombin (Va).

Hemostatic molecular markers, such as TAT and PTF1+2 for thrombin generation and D-dimer for fibrinolytic activity, are very sensitive for the detection of subtle progressions or regressions in consumption coagulopathy, thrombus formation and the subsequently induced fibrinolytic activities in the aorta. Changes in these marker levels might correlate with the morphology of the residual aortic dissection, such as extension or reduction in the dimension of the inner surface of the false lumen, the extent of thrombus formation, the stability of false lumen by endothelial cell proliferation or the dilatation of the aorta. Nakajima et al. described that these molecular markers strongly correlated with the maximal diameter of the aortic dissection and that coagulopathy progressively worsened in proportion to the degree of dilatation of the aorta in patients with aortic dissection.<sup>2)</sup>

Mean plasma levels of TAT and D-dimer were significantly higher in group 3 than in 1, while group 4 statistically failed to show significance as compared to 1 because of wide standard deviations. Even in group 3, some patients with low levels of TAT and/or D-dimer were repeatedly recognized. In these patients, proliferation of

endothelial cells over the subendothelial tissue of the false lumen, or the organization of the surface area of thrombus subsequently associated with less stimulant properties for thrombogenesis, might be possible mechanisms for stabilization of these hemostatic markers.

Maximal size of the aortic dissection is important information for deciding when surgical repair is required.<sup>11)</sup> Nakajima et al. described that  $\beta$ -TG, TAT and D-dimer strongly correlated with maximal diameter of the aortic dissection.<sup>2)</sup> However, in this study no correlations were detected in these markers except for PTF1+2.

In patients with fluctuating morphology of their aortic dissection, levels of the hemostatic markers, especially TAT and D-dimer, changed in correlation with the morphological variation of the aortic dissection, such as the extent of the lesion or the thrombogenic surface in chronic aortic dissection. In a progressive case (Fig. 5), D-dimer was elevated correlating to the morphological change of the aorta, meanwhile TAT steadily remained at high levels. TAT change is manifested only at the early phase of thrombus formation triggered by a burst of thrombin generation. Therefore, the apparent fluctuation of TAT levels might be difficult to detect when the timing of blood sampling is not coordinated. On the other hand, fluctuated levels of D-dimer in the blood are more likely to be sustained than TAT because D-dimer is produced by a slower process of fibrinolysis of established thrombus.

Serial measurement of D-dimer and TAT make it possible to predict morphological change in chronic aortic dissection without CT scans, making it an alternative noninvasive diagnostic method. In particular, it would benefit patients with renal failure or an allergic reaction to contrast dye. IMH sometimes progresses to overt aortic dissection or thrombosed dissection with an ulcer-like projection.<sup>12)</sup> Hemostatic marker determinations are useful for early prediction of morphological changes in cases where IMH insidiously progresses to an overt aortic dissection with intimal tear or vice versa.

There are some limitations to this study. We retrospectively compared hematological results and CT images at irregular times after onset of aortic dissection because of the shortness of the study period. Longer follow-up periods will be necessary in a serial prospective study to evaluate whether hematological changes actually correlate with CT images in aortic dissection.

## Conclusion

The morphology of aortic dissection was correlated with hemostatic molecular markers such as TAT or D-dimer. Serial measurement of D-dimer and TAT is useful to predict morphological changes in chronic aortic dissection, and is an alternative way to follow up aortic dissection patients.

## References

1. DeBakey ME, McCollum CH, Crawford ES, et al. Dissection and dissecting aneurysms of the aorta: twenty-year follow-up of five hundred twenty-seven patients treated surgically. *Surgery* 1982; **92**: 1118–34.
2. Nakajima T, Kin H, Minagawa Y, Komoda K, Izumoto H, Kawazoe K. Coagulopathy associated with residual dissection after surgical treatment of type A aortic dissection. *J Vasc Surg* 1997; **26**: 609–15.
3. Fine NL, Applebaum J, Elguezabal A, Castleman L. Multiple coagulation defects in association with dissecting aneurysm. *Arch Intern Med* 1967; **119**: 522–6.
4. McLeod AA, Cuddigan BJ, Mahon WE. Chronic haemorrhagic disorder induced by dissecting aortic aneurysm. *Eur Heart J* 1980; **1**: 409–11.
5. Bieger R, Vreeken J, Stibbe J, Loeliger EA. Arterial aneurysm as a cause of consumption coagulopathy. *N Engl J Med* 1971; **285**: 152–4.
6. Neri E, Toscano T, Massetti M. Operation for acute type aortic dissection in octogenarians. *J Thorac Cardiovasc Surg* 2001; **121**: 259–67.
7. Baumgartner HR, Stemerman MB, Spaet TH. Adhesion of blood platelets to subendothelial surface: distinct from adhesion to collagen. *Experientia* 1971; **27**: 283.
8. Straub PW, Kessler S. Umsatz und Lokalisation von I<sup>31</sup>-Fibrinogen bei chronischer intravasaler Gerinnung. *Schweiz Med Wochenschr* 1970; **100**: 2001–3.
9. Nakagawa T, Saito H, Watanabe Y, Sato M, Murakawa E. Coagulation and fibrinolysis parameters in disseminated intravascular coagulation (DIC). *Rinsho Byori* 1991; **39**: 309–14. (in Japanese)
10. Astrup T, Coccheri S. Thromboplastic and fibrinolytic activity of the arteriosclerotic human aorta. *Nature* 1962; **193**: 182.
11. Schor JS, Yerlioglu ME, Galla JD, Lansman SL, Ergin MA, Griep RB. Selective management of acute type B aortic dissection: long-term follow-up. *Ann Thorac Surg* 1996; **61**: 1339–41.
12. Moizumi Y, Komatsu T, Motoyoshi N, Tabayashi K. Management of patients with intramural hematoma involving the ascending aorta. *J Thorac Cardiovasc Surg* 2002; **124**: 918–24.