

## Kissing Pleural Metastases from Metastatic Osteosarcoma of the Lung

Takeshi Mori, MD, Masakazu Yoshioka, MD, Kazunori Iwatani, MD,  
Hironori Kobayashi, MD, Kentaro Yoshimoto, MD, and Hiroaki Nomori, MD, PhD

**Two patients with osteosarcoma lung metastases of which migrated to the parietal pleura due to contact are reported. The first patient was a 16-year-old male who had a pleural metastasis in the diaphragm within an area in contact with a single lung metastasis. Both of the tumors were resected, followed by systemic chemotherapy. Nine months after the resection of the first metastases, two other lung metastases were found which were resected after chemotherapy. The patient is alive without recurrence 84 months after the first resection of the metastases. The second patient was an 11-year-old female with a pleural metastasis of osteosarcoma which was within an area in contact with a single lung metastasis, which had been resected 4 months before. We concluded (1) that a lung metastasis of osteosarcoma occasionally metastasizes to the pleura due to contact; and (2) that because this kissing metastases of osteosarcoma could be cured by a complete resection, the intrathoracic cavity should be thoroughly observed. (Ann Thorac Cardiovasc Surg 2006; 12: 129–32)**

**Key words:** metastasectomy, lung, pleura

### Introduction

The lung is the most popular metastatic site of osteosarcoma. Jeffree et al. reported that osteosarcoma metastasized to the lung in over 90% of patients who died of osteosarcoma.<sup>1)</sup> According to the Japan Autopsy Annual Database, 643 patients died of osteosarcoma between 1981 and 2002 in Japan.<sup>2)</sup> Of the 643 patients, 78 (12.1%) had pleural metastases. We present two patients with metastases of parietal pleura which probably originated from a lung metastasis contacting the pleura, namely 'kissing metastases'.

### Case Report

#### Case 1

A 16-year-old male with femoral osteosarcoma received

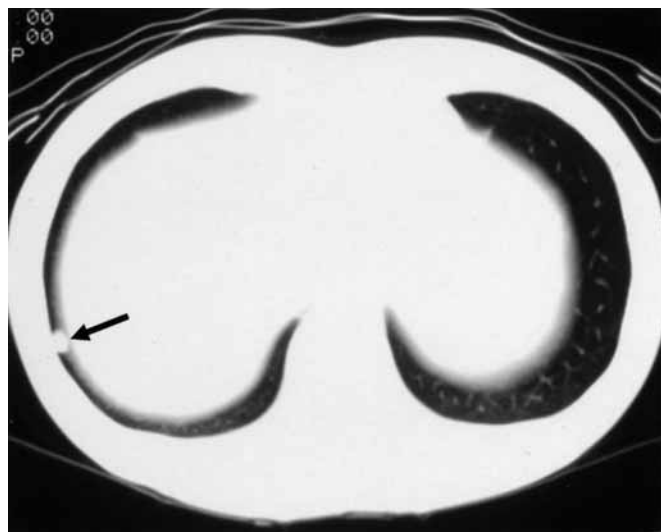
---

*From Department of Thoracic Surgery, Kumamoto University Graduate School of Medical Sciences, Kumamoto, Japan*

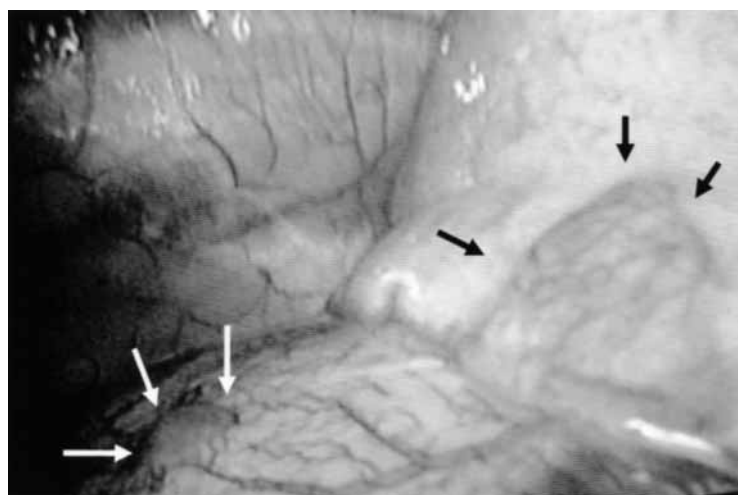
Received September 5, 2005; accepted for publication October 21, 2005.

Address reprint requests to Takeshi Mori, MD: Department of Thoracic Surgery, Kumamoto University Graduate School of Medical Sciences, 1-1-1 Honjo, Kumamoto 860-8556, Japan.

preoperative chemotherapy with cisplatin (CDDP) and doxorubicin (DXR), followed by an extended resection of the right femur and reconstruction in July 1997. Adjuvant chemotherapy with CDDP and cyclophosphamide (CPA) was continued for a total of 10 courses until June 1998. In September 1998, a single lung metastasis in the right lower lobe was found with computed tomography (CT) (Fig. 1). A needle biopsy was not performed. Thoracoscopy showed that a lung metastasis was located in the right lower lobe, and that it was exposed on the surface of the visceral pleura. Additionally, a solitary pleural tumor, 3 mm in size, was found on the diaphragm (Fig. 2). Although these two tumors were separated from each other, the pleural tumor was in an area that was in contact with the pulmonary tumor during ordinary lung expansion in ventilation. Both the lung and pleural tumors were resected. Pathological examination showed that both of the tumors were metastatic osteosarcoma, and that they were covered with a fibrous capsule but not with mesothelial epithelium. Adjuvant chemotherapy with ifosfamide (IFO) and DXR was administered after the first metastasectomy. In July of 1999, two additional lung metastases were detected by CT in the right upper and middle lobes. After chemotherapy with CPA, both me-



**Fig. 1.** Case 1.  
Computed tomography showing a single lung metastasis (arrow) in the right lower lobe near the pleura.



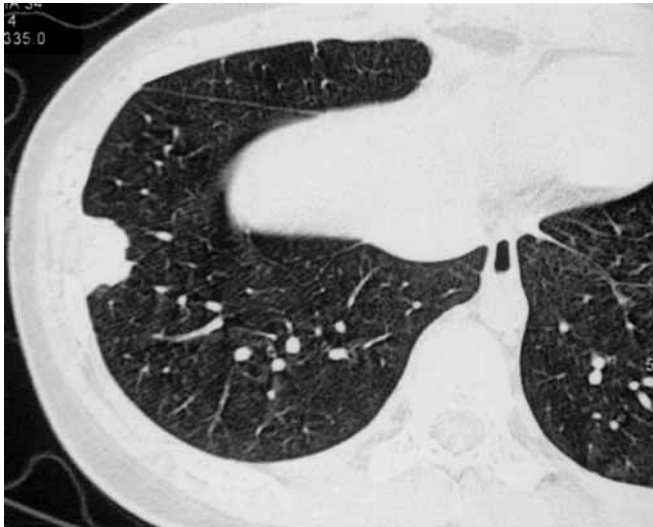**Fig. 2.** Case 1.  
The lung metastasis was located in the right lower lobe and was exposed on the visceral pleura (black arrows). The pleural metastasis was noted on the diaphragm which was in the area in contact with the lung metastasis (white arrows).

tastases were resected via thoracoscopy, but there were no pleural tumors at that time. Eighty one months after the first resection of metastases, the patient is alive and has not had a recurrence.

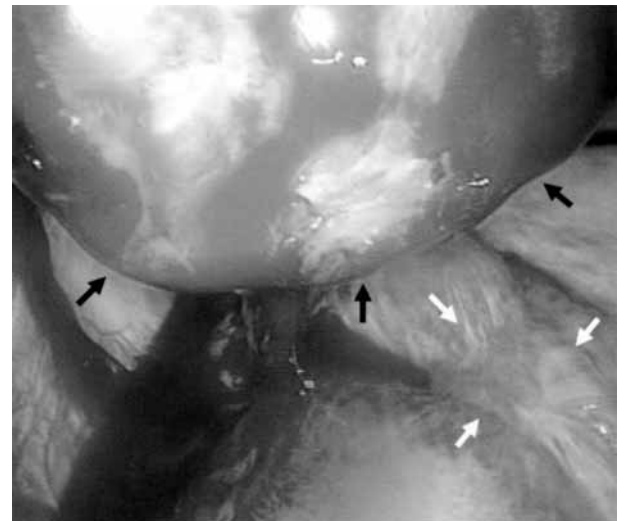
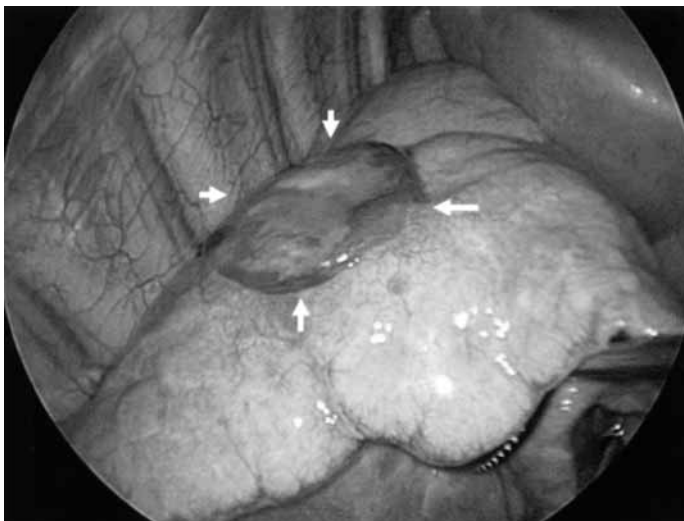
### Case 2

An 11-year-old female with femoral osteosarcoma underwent preoperative chemotherapy with CDDP and DXR, followed by an extended resection of the left femur and reconstruction in February 2003. Adjuvant chemotherapy with CDDP and CPA was administered for a total of 10 courses until January 2004. In October 2004, a single lung metastasis was found in the right lower lobe by CT. A needle biopsy was not performed. The thoracoscopy showed a lung metastasis which was located in

the right lower lobe which was exposed on the visceral pleura. Precise observation of the intrathoracic wall showed no other tumor on either the parietal or visceral pleura. The tumor was resected, followed by chemotherapy with IFO. The pathological diagnosis of the tumor was metastatic osteosarcoma. In March 2005, a pleural metastasis was found by CT (Fig. 3). The thoracoscopy showed a metastasis, 5.3 cm in size, located at the parietal pleura, within the area which was in contact with the scar of the first metastasectomy (Fig. 4). The pleural metastasis was completely resected with intercostals muscle. The pathological examination showed that the tumor was metastatic osteosarcoma and that it was covered with a fibrous capsule but not by mesothelial epithelium. The patient is now alive without recurrence 3 months after the last surgery.



**Fig. 3.** Case 2.  
Computed tomography of the pleural tumor showing extra-pleural signs.



**A**

**B**

**Fig. 4.** Case 2.

**A:** The metastatic pleural tumor which was exposed on the surface of the lung at first metastasectomy (arrows).

**B:** The metastatic pleural tumor (black arrows) was located on the parietal pleura in front of the scar (white arrows) of the first metastasectomy.

## Discussion

As far as we have reviewed, pleural metastasis due to contact with a lung metastasis of osteosarcoma has not yet been reported. Although the pleural metastases in these two patients may have been hematogenous, we believe that both pleural metastases occurred as a result of contact with the previous lung metastases for the following reasons: (1) Although the lung metastasis and pleural metastasis were completely separated from each other in

both of the two patients, the pleural metastases were within an area in contact with the lung metastasis during ordinary lung expansion in ventilation; and (2) Both the lung and pleural metastases in the two patients were covered with a fibrous capsule but not by mesothelial epithelium; and (3) After resection of the pleural metastasis, the first patient has not suffered another pleural metastasis or dissemination for over 6 years, which could be explained by the pleural metastasis originating from contact with the lung tumor rather than a hematogenous metastasis or a

dissemination. Although we do not entirely deny the possibility of a hematogenous metastasis or dissemination, it can be surmised that the pleural metastasis of osteosarcoma could occasionally originate from a 'kissing metastases' to the pleura near the site of the lung metastasis, as in the present two cases. While patients with lung metastasis from osteosarcoma usually had bloody pleural effusion, pleural metastasis was rarely found with lung metastasis of osteosarcoma, which was contrary to lung metastasis from carcinoma. Although kissing pleural metastases of osteosarcoma have not been reported before, Nomori et al. reported a patient with a kissing metastases of a fibrous tumor of the pleura.<sup>3)</sup> We believe that the kissing metastases could also occur in other kinds of intrathoracic neoplasms, especially in sarcoma rather than carcinoma.

Skinner et al. reported that a 5-year survival rate in the patients with pulmonary metastases of osteosarcoma was 41% after metastasectomy and systemic chemotherapy.<sup>4)</sup> Because a kissing pleural metastases of osteosarcoma can

be cured after complete resection, we conclude that the pleural cavity in contact with the lung metastasis should be thoroughly observed under a thoracoscopy. Whenever a metastasizing pleural tumor is found within the area in contact with the lung metastasis, the lesions and the surrounding pleura should be resected completely, which could improve the prognosis of patients.

## References

1. Jeffree GM, Price CH, Sissons HA. The metastatic patterns of osteosarcoma. *Br J Cancer* 1975; **32**: 87–107.
2. Japanese Society of Pathology. Japan Autopsy Annual Database. Tokyo: Japanese Society of Pathology. (in Jpse.)
3. Nomori H, Horio H, Fuyuno G, Morinaga S. Contacting metastasis of a fibrous tumor of the pleura. *Eur J Cardiothorac Surg* 1997; **12**: 928–30.
4. Skinner KA, Eilber FR, Holmes EC, Eckardt J, Rosen G. Surgical treatment and chemotherapy for pulmonary metastases from osteosarcoma. *Arch Surg* 1992; **127**: 1065–71.