

Surgical Treatment of Achalasia: Transabdominal Versus Transthoracic Cardiomyotomy

Reza Bagheri, MD,¹ S. Ziaallah Haghi, MD,¹ and Sadjad Noorshafiee, MD²

Background: Achalasia is a primary esophageal motor disorder involving the body of the esophagus and lower esophageal sphincter. The mechanism is destruction of the myenteric plexus after a viral infection. Multiple methods of treatment with variable results induced in achalasia.

Materials and Methods: We analyzed 70 patients with achalasia that underwent surgical treatment with transabdominal or transthoracic cardiomyotomy from 1982 to 2008 in Mashhad (Ghaem and Omid) hospital and at least 2 years follow up for evaluated result of surgery.

Results: The mean age was 39.2 ± 9.42 years and the M/F = 0.89. The most common symptom was dysphagia (100%). The interval between beginnings of symptoms to a definitive diagnosis was 10.6 ± 8.3 month. The ratio between the two techniques was 35/35 = 1. In 67.1% of patients, a previous history of pneumatic dilation was reported. Long-term good results after surgery were seen in 77.2% of patients. Recurrence after surgical treatment was seen in 22.8%. A comparison of the two techniques (with or without antireflux surgery), showed a greater failure rate in transabdominal cardiomyotomy without the antireflux protocol (8/15 = 40%), but by the chi-square test, the difference was not statistically significant (P = 0.107). The most common complication after surgery was esophageal leakage (2.85%), and mortality was zero. In recurrence, most patients underwent pneumatic dilation (9/16 = 56.2%), and if surgery was needed, all patients underwent a transthoracic approach with antireflux treatment.

Conclusion: Based on the good, long-term results with the surgical treatment of achalasia, surgery is recommended in most patients. A transthoracic or transabdominal approach had good, long-term results, but a transthoracic approach had better results and usually did not need antireflux surgery.

Key words: achalasia- cardiomyotomy, transthoracic, transabdominal

¹Thoracic Surgery, Mashhad University of Medical Sciences, Ahmad Abad Street, Mashhad, Iran

²General Surgery, Mashhad University of Medical Sciences, Ahmad Abad Street, Mashhad, Iran

Received: September 25, 2009; Accepted: May 27, 2010

Corresponding author: Reza Bagheri MD. Thoracic Surgery, Mashhad University of Medical Sciences, Ahmad Abad Street, Mashhad, Iran

Email: Bagherir@mums.ac.ir

©2011 The Editorial Committee of *Annals of Thoracic and Cardiovascular Surgery*. All rights reserved.

Introduction

Achalasia is a primary motor disorder of the esophagus. Characteristic of this disorder is the inability to relax the lower esophageal sphincter.¹⁾ The etiologic factor of this disease is a viral infection, especially varicella zoster. Pathophysiologically, a selective reduction occurs in inhibitory neurons in the esophageal wall that leads to the destruction of white muscle in lower esophageal sphincter (LES).²⁾ The most common histopathologic finding in primary achalasia is a reduction in myenteric

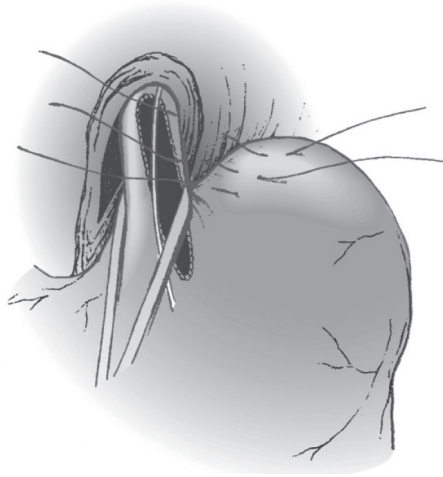


Fig. 1 Transabdominal cardiomyotomy Technique which is associated with partial fundoplication.²²⁾

ganglion cells. The main cause is unknown, but autoimmune process is victim.³⁾

Achalasia is seen in any age, but most patients are between 20 to 50 years old. Due to the slow process of diseases, this disorder is not diagnosed in the primary stages. Symptoms of Achalasia are dysphagia, mild regurgitation, aspiration, Chest pain and weight loss.⁴⁾ The main purpose in the treatment of Achalasia is to reduce LES pressure to alleviate symptoms such as dysphagia, regurgitation, coughing and choking.⁵⁾ Most gastroenterologists have good results with pneumatic dilation or, in special cases, with botulinum toxin injection. They believe that surgery is indicated only in the failure of these approaches.^{1,6)}

Surgical treatment of Achalasia was performed by heller with transabdominal anterior & posterior cardio myotomy of LES. In 1958, Ellis treated Achalasia with a transthoracic technique⁷⁻⁹⁾; recently, laparoscopic myotomy with partial fundoplication is performed.^{10, 11)} We purpose to compare two conventional methods in the treatment of Achalasia (transabdominal versus transthoracic myotomy).

Material and Methods

All patients with Achalasia who underwent surgery in Quaem and Omid hospitals in Mashhad University of Medical Sciences of Iran, between 1982 and 2008, were studied and followed up for 2 years. The diagnosis of Achalasia was made according to history, chest

X-Ray, Barium swallow, upper GI endoscopy and esophageal manometry. Indications of surgical intervention consist of failure in non-invasive treatment and include endoscopic pneumatic dilatation and dysphagia as a primary presentation. Choosing the technique was the surgeon's desire, and surgery was performed by two surgeons.

Patient data such as age, sex, symptom duration before surgery, clinical signs, history of pervious treatment, type of treatment, treatment complications, rate of symptom recurrence after treatment (persistently of previous symptom with radiologic adjustment) were analyzed with SPSS Ver 11.5.

Then, for comparison of transthoracic and transabdominal techniques, X-Square and students T test and Mann-Whitney methods were used, and P value <0.05 was valuable.

Technique

In the transabdominal technique, the patient was in a supine position, and a midline incision (from xyphoid to umbilicus) was used. Firstly, the left lobe of the liver was detached, and the abdominal esophagus was exposed. Then, a plastic bougie (40 F) was inserted from the mouth to the stomach. Myotomy was performed on the esophagus and stomach. If myotomy was long on the stomach, then a partial fundoplication was performed (**Fig. 1**).

In a transthoracic technique, a thoracotomy was done with a posterolateral incision on the left side in 6 or 7 intercostal spaces (the average length of thoracotomy incision was 12 cm). Before the intubation, a 40 F plastic bougie was inserted from the mouth to the stomach. Firstly, the inferior pulmonary ligament was detached which retracted the cephalad. Then, the esophagus was exposed, and myotomy was performed on the stomach (Just 1cm after vein of myo) and the esophagus (up to interior pulmonary vein). The myotomy edges were dissected from the mucosa circumferentially (180°) from both sides. If hiatus was manipulated, a partial fundoplication was performed (**Fig. 2**).

Results

The 70 patients enrolled in our study had a mean age of 39.2 ± 9.42 years (ranged 18–56 years). The mean weight before the operation was 62.6 kg (45.5 to 78.5) kg. The male to female ratio was 33/ 37 (0.89%). The mean follow-up duration was 34.6 ± 12.14 months. The most




Fig. 2 Transthoracic approach; **A:** The long myotomy incision is made on esophagus and stomach using Mayo scissors. **B:** The edges of myotomy should be dissected laterally from mucosa in both directions of circular muscles.²²⁾ A | B

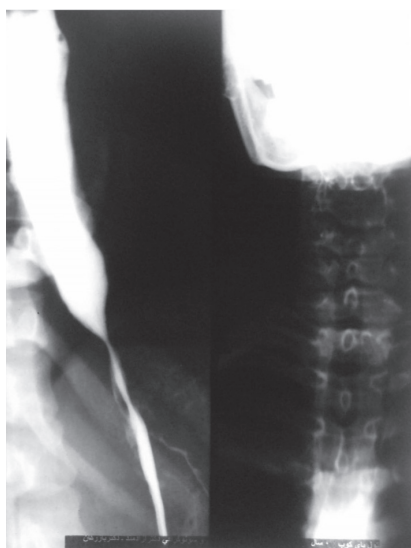

Fig. 3 Radiologic pattern of achalasia.

common symptom was dysphagia and mean duration between the beginning of symptoms to a definitive diagnosis was 10.6 ± 8.3 months. CXR, Barium swallow was performed in all patients for the diagnosis (**Fig. 3**). In view of the radiologic manifestation, Achalasia patients were divided into three groups containing 42 patients with spindle form (60%) and 24 patients with flask form (34.2%) and 4 patients (5.7%) with sigmoid type of Achalasia. To rule out cancer (pseudoachalasia) in all patients, endoscopy was performed. Manometry was performed in 60 patients (85.7%).

A previous history of achalasia treatment (pneumatic dilation) was recorded in 67.1% of cases. 35 patients (14 male and 21 female) underwent a transabdominal

approach, and 35 patients (19 male and 16 female) underwent a transthoracic approach. Comparing these findings between the 4 subgroups (transabdominal versus transthoracic with or without partial fundoplication) according to the therapeutic approach is shown in **Table 1**.

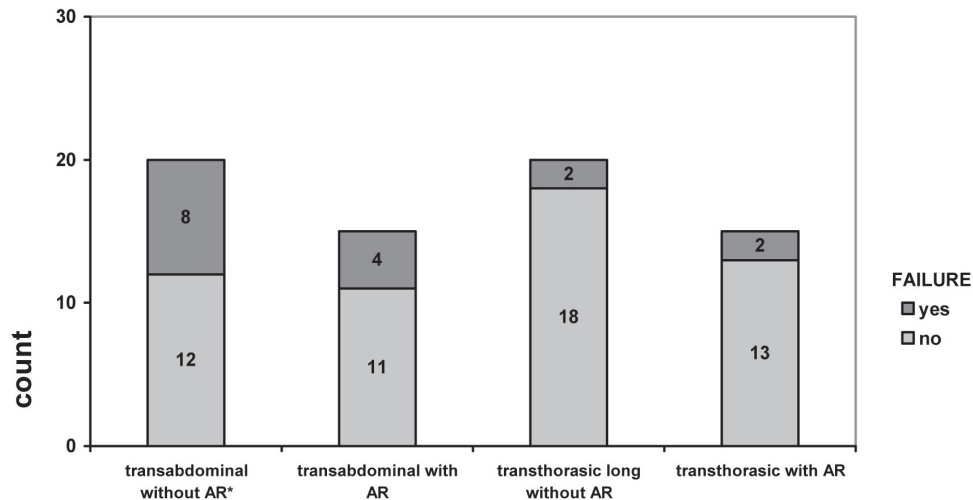
Among 35 patients who were treated by transabdominal approach, 20 cases underwent short cardimyotomy without antireflux procedure and 15 cases underwent long myotomy with Toupet fundoplication. Among 35 patients who were treated by a transthoracic approach, 20 patients underwent pure long myotomy without an antireflux procedure, and 15 cases underwent long myotomy with Belsey mark IV fundoplication. (**Fig. 2**)

The treatment response was assessed in all patients during at least the 2-year follow up, and symptomatic patients underwent reevaluation for the diagnosis of treatment failure. Postoperative weight gain was 5.8 kg in transabdominal group and 6.1 in the transthoracic group (P value >0.05). Post operative complications were seen in 3 patients (4.28%), 2 patients had esophageal leakage, and 1 patient had wound infection. Esophageal leakage controlled with medical treatment.

Treatment failure was reported in 16 patients (22.8%), 8 of these patients were in the transabdominal cardimyotomy without antireflux procedure group, 4 patients, in transabdominal long myotomy with Toupet fundoplication group, 2 cases, in transthoracic long myotomy without antireflux group and 2 cases, in transthoracic long myotomy with Belsey mark IV fundoplication. Comparing treatment failure rates between different groups by the chi-square test, the difference was not statistically significant (P = 0.107) although failure was more frequent in

Table 1 Characteristics of patients with achalasia who underwent surgical treatment with four different approaches

Variable	Transabdominal cardimyotomy without antireflux procedure	Transabdominal long myotomy with Toupet fundoplication	Transthoracic long myotomy without antireflux	Transthoracic long myotomy with Belsey mark IV fundoplication	P value
N	20	15	20	15	-
Age(year)	40.5 ± 6.32	44.1 ± 8.67	36.2 ± 10.64	36.5 ± 10.62	0.039
Sex(M/F)	9/11	5/10	11/9	8/7	0.591
Previous treatment	11(55%)	11(73.3%)	15(75%)	10(66.7%)	0.540
Follow up(month)	29.3 ± 9.62	37.6 ± 11.83	27.1 ± 13.27	30.2 ± 12.19	0.081

**Fig. 4** Frequency of treatment failure among patients with achalasia who underwent surgical treatment with four different approaches. AR, antireflux surgery**Table 2** Characteristics of patients with achalasia who underwent surgical treatment with four different approaches

Variable	Transabdominal cardimyotomy without antireflux procedure	Transabdominal long myotomy with Toupet fundoplication	Transthoracic long myotomy without antireflux	Transthoracic long myotomy with Belsey mark IV fundoplication
Number	20	15	20	15
success	12	11	18	13
Failure	8	4	2	2
-Dilatation	3	2	2	2
--Re-operation	5	2	-	-

the transabdominal cardimyotomy without antireflux procedure group.

All patients with recurrent symptoms were managed either by dilatation or re-operation, and the final results are shown in **Table 2**.

In the recurrence patient, surgery was performed with a transthoracic approach with or without Belsey Mark IV antireflux surgery. Mortality was zero.

Discussion

Achalasia is a primary motor disorder of the esophagus, usually involving body and LES. The patients who presented with dysphasia were on a solid and liquid diet. Often after performing barium swallow imaging and endoscopy, the diagnosis is confirmed with esophageal manometry.⁴⁾

Achalasia has no definitive therapy, because it is impossible to make the esophagus functional after denervation, but the aim of treatment is to lower the LES pressure to permit food passage.¹²⁾ Treatment strategies for achalasia are pneumatic dilation, botulinum toxin injection, surgical cardio myotomy (transabdominal or transthoracic; open or laparoscopic) according to different treatment outcomes, the technique of choice should be based on patient desire, and the surgeon's ability and familiarity with techniques. The decision is different in different patients.¹³⁾

In a study by Boztas and et al, they report successful treatment with pneumatic dilation in 80%.¹⁴⁾ In another study by Bonavina and et al, they concluded that endoscopic treatment (if needed) did not increase the risk of surgery.¹⁵⁾

In another study by Allescher and et al, an old patient who had a higher risk for other treatments, had gone under botulinum injection via endoscopy in LES. They concluded that this method is a safe and cost-effective one. The other benefit is the capability of performing this method as an out patient.⁶⁾

If these approaches were not effective because of any reason, surgical treatments should be considered. The main purposes of all these techniques are to lower the LES pressure and destruction of the spastic state. Then, the first surgical approach is used by Ernest Heller for the successful treatment of achalasia and named cardio-myotomy. In this procedure, two long myotomy was performed in the anterior and posterior of the esophagus from 8cm of distal of the esophagus to the proximal of the cardia. All symptoms of patients were relieved, but most of them experience sever gastro esophageal reflux.¹⁶⁾

In 1918, De brune and et al had modified this technique, and only one cardiomyotomy was done on the anterior surface of the esophagus. This technique is known as the heller technique and is the surgical treatment of achalasia for the past 85 years.¹⁷⁾

Many surgeons choose an abdominal approach. A study by Abir and Colleagues was performed on 2680 patient with this approach. The success rate was reported to be 83%, and the mortality was low. The only complication was a small perforation in the esophagus during cardiomyotomy and post operative Gastro esophageal reflux.¹⁷⁾

Although, today, many surgeons perform this procedure laparoscopically as the first step, but all of them believe that in spite of all benefits of this method includ-

ing minor tissue trauma and the lower rate of post operative reflux, the risk of microperforation was higher, and surgeon expertise is so important. Passing the learning curve is essential for a correct and non complicated procedure.¹⁸⁾

Many surgeons believe that, by a transabdominal technique, the rate of gastroesophageal reflux disease (GERD) is higher because of manipulation on the hiatus and esophagophrenic ligament. Those who choose a transthoracic technique believe that it is easier and more careful. In a study by Gaissert and Colligues on 64 patients with achalasia who underwent transthoracic procedure, the success rate was 91%. They believe that they have very low mortality and morbidity. An anti reflux procedure is rarely needed.¹⁹⁾ But in a comparison by Abir and colligued about the success rate of these two techniques (transthoracic or transabdominal) they conclude that there is no difference in these approaches, but morbidity was higher in abdominal procedure.¹⁷⁾

The other point that is controversial between surgeons is the length of myotomy on the esophagus. Many investigators emphasize that the greater the length of myotomy, the more chance there is to control the dysphagia.²⁰⁾

There are many studies about the necessities of anti reflux surgery. Of course, it is controversial and dependent on the surgeon's opinion during the operation for preventing GERD, and the surgeon should make a decision individually (dependent on manipulation of hiatus).²¹⁾

Conclusion

Regarding low mortality and morbidity and complications in the surgical treatment of achalasia, it could be performed as an alternative modality after unsuccessful endoscopic treatment, even though it could be the first line of treatment, which is independent on the patient's desire and the surgeon's experience.

We conclude that there was no meaningful difference in the success rate and complications, though the treatment failure rate in patients with a transabdominal technique without an anti reflux procedure was higher.

Acknowledgment

The authors appreciate research committee of Mashhad University of Medical Sciences for financial support and are thankful Dr. Shojaeian and Dr. Afzalghaei and

Dr. Elahe Bagheri for composing this article.

References

- 1) Kaufman JA, Lal DR, Oelschlager BK. Surgical treatment for achalasia. *GI Motility online* (2006). Available at URL:<http://www.Nature.com>. Accessed Feb 20, 2009.
- 2) Raymond L, Lach B, Shamji FM. Inflammatory aetiology of primary oesophageal achalasia: an immunohistochemical and ultrastructural study of Auerbach's plexus. *Histopathology* 1999; **35**: 445-53.
- 3) Wong RK, Maydonovitch CL, Metz SJ, Baker JR. Significant DQw1 association in achalasia. *Dig Dis Sci* 1989; **34**: 349-52.
- 4) Pohl D, Tutuian R. Achlasia: an overview of diagnosis and treatment. *J Gastrointestin Liver Dis* 2007; **16**: 297-303.
- 5) Hoogerwerf WA, Pasricha PJ. Achlasia: treatment options revisited. *Can J Gastroenterol* 2000; **14**: 406-9.
- 6) Allescher HD, Storr M, Seige M, Gonzales-Donoso R, Ott R, et al. Treatment of achlasia: Botulinum toxin injection vs. pneumatic balloon dilation. Aprospective study with long-term follow-Up. *Endoscopy* 2001; **33**: 1007-17.
- 7) Wright AS, Williams CW, Pellegrini CA, Oelschlager BK. Long-term outcomes confirm the superior efficacy of extended Heller myotomy with Toupet fundoplication for achalasia. *Surg Endosc* 2007; **21**: 713-8.
- 8) Stewart KC, Finley RJ, Clifton JC, Graham AJ, Storseth C, et al. Thoracoscopic versus laparoscopic modified Heller Myotomy for achalasia efficacy and safety in 87 patients. *J Am Coll Surg* 1999; **189**: 164-70.
- 9) Ellis FH Jr, Olsen AM, Holman CB, Code CF. Surgical treatment of cardiospasm (achalasia of the esophagus); considerations of aspects of esophagomyotomy. *J Am Med Assoc* 1958; **166**: 29-36.
- 10) Shimi S, Nathanson LK, Cuschieri A. Laparoscopic cardiomyotomy for achalasia. *J R Coll Surg Edinb* 1991; **36**: 152-4.
- 11) Zaninotto G, Costantini M, Portale G, Battaglia G, Molena D, et al. Etiology, diagnosis, and treatment of failures after laparoscopic Heller myotomy for achalasia. *Ann Surg* 2002; **235**: 186-92.
- 12) Peracchia A, Bonavina L. Achlasia: dilation, injection or surgery? *Can J Gastroenterol* 2000; **14**: 441-3.
- 13) Urbach DR, Hansen PD, Khajanchee YS, Swanstrom LL. A decision analysis of the optimal initial approach to achalasia: laparoscopic Heller myotomy with partial fundoplication, thoracoscopic Heller myotomy, pneumatic dilatation, or botulinum toxin injection. *J Gastrointest Surg* 2001; **5**: 192-205.
- 14) Boztas G, Mungan Z, Ozdil S, Akyuz F, Karaca C, et al. Pneumatic balloon dilatation in primary achalasia: the long-term follow-up results. *Hepatogastroenterology* 2005; **52**: 475-80.
- 15) Bonavina L, Incarbone R, Antoniazzi L, Reitano M, Peracchia A. Previous endoscopic treatment does not affect complication rate and outcome of laparoscopic Heller myotomy and anterior fundoplication for oesophageal achalasia. *Ital J Gastroenterol Hepatol* 1999; **31**: 827-30.
- 16) Heller E. Extramucose cardioplastie beim chronischen cardiospasmus mit dilatation des oesophagus. *Mitt Grenggeb Med Chir* 1913; **2**: 141-9.
- 17) Abir F, Modlin I, Kidd M, Bell R. Surgical treatment of achalasia: current status and controversies. *Dig Surg* 2004; **21**: 165-76.
- 18) Luketich JD, Fernando HC, Christie NA, Buenaventura PO, Keenan RJ, et al. Outcomes after minimally invasive esophagomyotomy. *Ann Thorac Surg* 2001; **72**: 1909-13.
- 19) Gaissert HA, Lin N, Wain JC, Fankhauser G, Wright CD, et al. Transthoracic Heller myotomy for esophageal achalasia: analysis of long-term results. *Ann Thorac Surg* 2006; **81**: 2044-9.
- 20) Patti MG, Pellegrini CA, Horgan S, Arcerito M, Omelanczuk P, et al. Minimally invasive surgery for achalasia: an 8-year experience with 168 patients. *Ann Surg* 1999; **230**: 587-93.
- 21) Junginger T, Kneist W, Sultanov F, Eckardt VF. [Long-term outcome of myotomy and semi-fundoplication in achalasia]. *Chirurg* 2002; **73**: 704-9. (in German)
- 22) Surgical approaches for primary motor disorders of the esophagus, Richard J Finley: *Pearson's thoracic and esophageal surgery*. Philadelphia: Churchill-Livingstone, 2008; pp 746, 750.